

DORSAL WEDGE OSTEOTOMY OF THE PROXIMAL PHALANX FOR HALLUX RIGIDUS

LONG-TERM RESULTS

NEIL CITRON, MICHAEL NEIL

From the Royal National Orthopaedic Hospital and St Mary's Hospital, London

Eight women had 10 toes treated for hallux rigidus by dorsal wedge osteotomy of the proximal phalanx and were reviewed after an average follow-up of 22 years. Five toes were symptom-free, four others did not restrict walking, and only one had required metatarsophalangeal fusion. We conclude that dorsal wedge osteotomy affords long-lasting benefits for hallux rigidus in the adolescent female.

Dorsal wedge osteotomy of the proximal phalanx for hallux rigidus was first proposed by Bonney and Macnab in 1952, and short-term results were reported by Kessel and Bonney in 1958. The aim of the operation is to move the limited arc of movement at the affected joint to a more dorsiflexed position so that function is improved. The purpose of this study was to assess its long-term results.

MATERIALS AND METHODS

A review of case notes from the Royal National Orthopaedic Hospital and St Mary's Hospital, London revealed 15 patients, all females, who had undergone a dorsal wedge osteotomy at least 10 years previously. An attempt was made to review these patients at a special follow-up clinic. Only eight attended, which was hardly surprising in view of the youth of some of the patients at the time of operation and the length of the follow-up.

The age of the patients at operation ranged from 10 to 52 years, with a mean of 23 years. Symptoms in each toe had persisted from two months to 15 years before operation with a mean duration of four years. The length of follow-up was 11 to 29 years, with an average of 22 years per toe.

Four patients had an initial history of injury to the great toe. Two patients had had bilateral procedures and one patient had undergone an arthrodesis three years after the initial procedure (this case was therefore regarded as a failure). There were thus five right and five left toes for evaluation.

RESULTS

The findings before and after operation are shown in Table I.

Pain relief. All patients experienced complete relief of pain shortly after the osteotomy, and in five of the 10 toes (50%) this relief was permanent.

Patient 1 developed pain in the hallux five years after operation and, at present, this only troubles her when she dances and is related to a corn on the lateral side of the plantar surface of her interphalangeal joint (due to supination at the osteotomy site).

Patient 2, who had bilateral procedures at the age of 18, later became an international netball player. At follow-up 29 years later the left toe was still free from pain, but in the past four years she had noted a slight discomfort in the right toe after playing tennis for more than an hour.

Patient 4 had been painfree for 13 years after operation but then required interphalangeal joint fusion for degenerative changes. Since then she has been painfree, but has some difficulty climbing stairs and walking over uneven ground.

Patient 6 had relief of pain for only six months after a procedure on the right toe at the age of 41; the procedure was repeated 11 years later when the left toe was also treated. When last seen at follow-up 11 years later, both toes were asymptomatic.

N. Citron, FRCS, Senior Orthopaedic Registrar
M. Neil, FRACS, Senior Orthopaedic Registrar
Royal National Orthopaedic Hospital, 45-51 Bolsover Street, London
W1P 8AQ, England.

Request for reprints should be sent to Mr N. Citron.

© 1987 British Editorial Society of Bone and Joint Surgery
0301-620X/87/5138 \$2.00

Table I. Findings before and results after dorsal wedge osteotomy in eight patients (10 toes)

Patient number	Side	Before operation					Range of movements (degrees)†				Postoperative radiological changes
		Duration of symptoms (years)	Radiographic changes	Age at operation (years)	Length of follow-up (years)	Complete pain relief (years)	Before operation		After operation		
							MTJP	IPJ	MTJP	IPJ	
1	L	19	Minimal	32	17	No (but pain much less)	10-20	45-60	15-5	45-75	Yes
2	R	4	None	18	29	25	20-30	15-35	0-5	15-30	Moderate
3	L	4	Minimal	18	29	29	15-45	50-0	0-20	45-60	Moderate
4	R	5	Minimal	16	28	28	10-45	40-30	0-20	85-15	Minimal
5	L	0.16	None	18	25	13 (IPJ fusion aged 34)			14-40	Fused	Minimal
6	R	Unknown	Unknown	15	20	20	50-35	*	40-50	40-60	Minimal
7	R	3	Unknown	52	11	11	25-5	*	30-0	0-55	Moderate
8	L	3	Unknown	41	22	0.5	*	*	*	*	Moderate
				(repeated at 52)		11	5-5	*	45-0	0-25	Moderate
7	L	3	None	23	15	15	55-20	*	55-0	0-40	None
8	R	0.5	Unknown	10	—	(Fusion aged 13)	—	—	—	—	None

MTPJ, metatarsophalangeal joint
IPJ, interphalangeal joint

* Not in clinical notes
† Plantarflexion-dorsiflexion

Patient 8, the youngest patient in the series, underwent surgery when 10 years old and was symptom-free for several months after operation. She then caught her toe on a carpet and subsequently developed pain and non-union at the osteotomy site. Revision to an arthrodesis was eventually required. She was the only patient who required fusion of the metatarsophalangeal joint.

Activity. All the patients we reviewed could walk for an unlimited distance except for Patient 3 who had a bunion over a dorsal osteophyte of the metatarsophalangeal joint and complained of occasional aching after a long time on

her feet. Most patients were able to participate in restricted sporting activities, but had to wear flat shoes.

Footwear. Patient 3 had some difficulty with footwear because of a dorsal osteophyte at the base of the proximal phalanx. No patient could tolerate a heel more than 3 or 4 cm high and most stated that they preferred thicker-soled shoes when walking.

Range of movements. These are shown diagrammatically in Figure 1.

Radiographic changes. Where records were available, radiographs showed a slow deterioration of the metatarsophalangeal joint, mainly due to osteophyte formation rather than loss of joint space (Figs 2 and 3). We were unable to document any radiological improvement in the joint space after operation at any stage in any patient.

Other symptoms. Patient 3 complained of slight aching in the metatarsophalangeal joint in cold weather, while Patient 6 complained of some discomfort over the scars

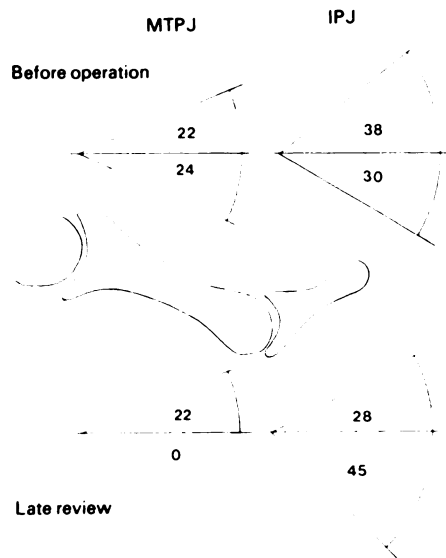
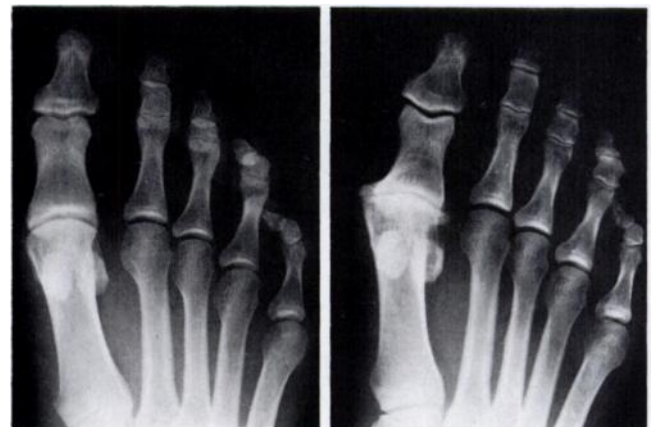**Fig. 1**

Diagram to show the mean ranges of movement of the first metatarsophalangeal joint (MTPJ) and the interphalangeal joint (IPJ) before the operation and at review.

**Fig. 2****Fig. 3**

Anteroposterior radiographs showing the right foot of Patient 2, before operation (Fig. 2) and at review 29 years later (Fig. 3).

from the bilateral procedures. In the other patients cold was well tolerated and the scars were not tender.

DISCUSSION

Bonney and Kessel's (1958) report of excellent short-term results after a dorsal wedge osteotomy only described 10 toes, and other authors have presented similarly small series (Heany 1970; Harrison 1971; Moberg 1979). Although the number of patients in our own series also is small, they are long-term and we feel they are sufficient to draw some conclusions.

In our series, good results were obtained in toes which had very little plantarflexion and in those with pre-existing radiographic changes, although none of the patients had severe degenerative changes pre-operatively (McMaster 1978; Fixsen 1983; Harris 1983). Although the average age at operation in our series was higher than that initially recommended, this did not prejudice the results, indicating that the operation may have a wider application than previously reported. All our patients were female and, in all except one, symptoms first appeared during adolescence, that is, when they were less than 20 years old.

In the majority of cases the osteotomy had been held in plaster, and the skin alone was sutured. It seems to be especially important to avoid supination of the distal fragment as this can lead to callosity formation, a problem previously noted with arthrodesis of the first metatarsophalangeal joint (Fitzgerald 1969).

We found that, after the osteotomy, there was a loss of movement in the metatarsophalangeal joint, but that dorsiflexion was still possible. The loss of movement was consistent with the radiographic changes we observed. The arc of movement of the interphalangeal joint was shifted towards plantarflexion as if in compensation, and one patient developed osteoarthritis of the interphalangeal joint which then required fusion. A similar problem has been reported after arthrodesis of the first metatarsophalangeal joint with a high incidence of radiographic and clinical degenerative arthritis of the interphalangeal joint at long-term follow-up (Moynihan 1967; Fitzgerald 1969).

After operation, clinical results with regard to relief of pain were excellent, with half the joints completely painfree at follow-up. There were two technical failures

in the series: one patient had supination of the distal fragment while another had non-union after trauma during the healing phase and this patient was eventually treated by arthrodesis.

Seven of the other eight patients had unlimited and painfree walking ability, and all except two could participate in activities such as tennis or dancing. The one patient with pain had only an occasional ache in the toe but her walking was not limited. The radiographic deterioration in the metatarsophalangeal joint seen after operation did not correspond with the clinical findings, and most patients remained asymptomatic.

Other procedures have been described for hallux rigidus including Keller's arthroplasty (Bonney and Macnab 1952), and Silastic interposition arthroplasty (Wenger and Whalley 1978), but their long-term results are either inferior or as yet unavailable.

Our results lead us to agree with Harris (1983) that dorsal wedge osteotomy of the proximal phalanx is the procedure of choice for hallux rigidus in adolescents with no radiographic evidence of osteoarthritis.

We would like to thank Mr Basil Helal for his helpful comments, the Photographic Department at the Royal National Orthopaedic Hospital for the photographic illustrations, and Ms Elise Marcus for her help in preparing Figure 1.

REFERENCES

- Bonney G, Macnab I.** Hallux valgus and hallux rigidus: a critical survey of operative results. *J Bone Joint Surg [Br]* 1952;34-B:366-85.
- Fitzgerald JAW.** A review of long-term results of arthrodesis of the first metatarso-phalangeal joint. *J Bone Joint Surg [Br]* 1969; 51-B:488-93.
- Fixsen JA.** Hallux valgus and hallux rigidus. In: Harris NH, ed. *Postgraduate textbook of clinical orthopaedics*. Bristol etc: Wright PSG, 1983:166-7.
- Harris NH.** Hallux rigidus. In: Harris NH, ed. *Postgraduate textbook of clinical orthopaedics*. Bristol etc: Wright PSG, 1983:859-60.
- Harrison M.** Hallux limitus. *J Bone Joint Surg [Br]* 1971;53-B:772.
- Heany SH.** Phalangeal osteotomy for hallux rigidus. *J Bone Joint Surg [Br]* 1970;52-B:799.
- Kessel L, Bonney G.** Hallux rigidus in the adolescent. *J Bone Joint Surg [Br]* 1958;40-B:668-73.
- McMaster MJ.** The pathogenesis of hallux rigidus. *J Bone Joint Surg [Br]* 1978;60-B:82-7.
- Moberg E.** A simple operation for hallux rigidus. *Clin Orthop* 1979;142:55-6.
- Moynihan FJ.** Arthrodesis of the metatarso-phalangeal joint of the great toe. *J Bone Joint Surg [Br]* 1967;49-B: 544-51.
- Wenger RJJ, Whalley RC.** Total replacement of the first metatarsophalangeal joint. *J Bone Joint Surg [Br]* 1978;60-B:88-92.